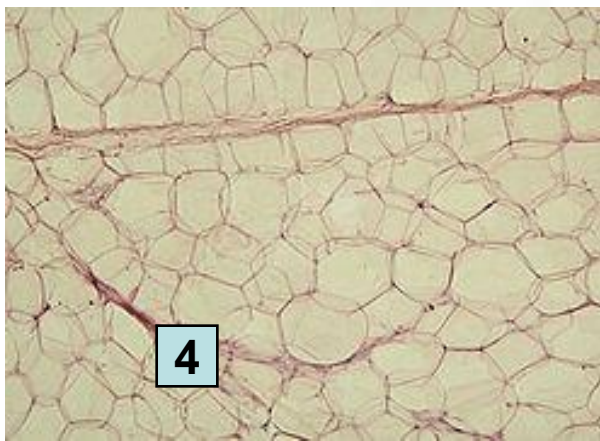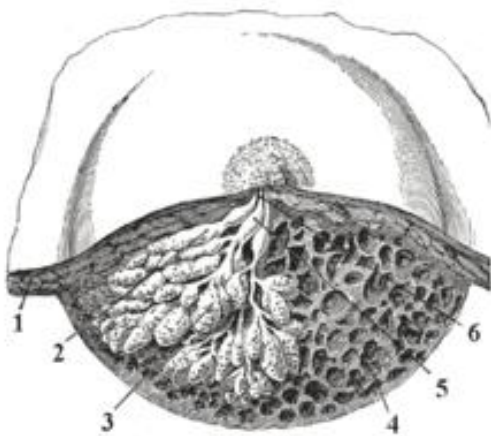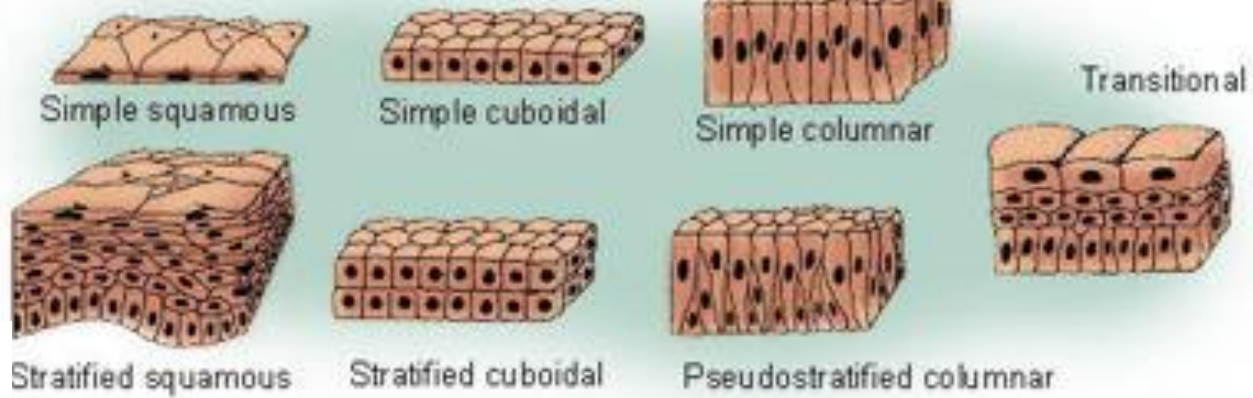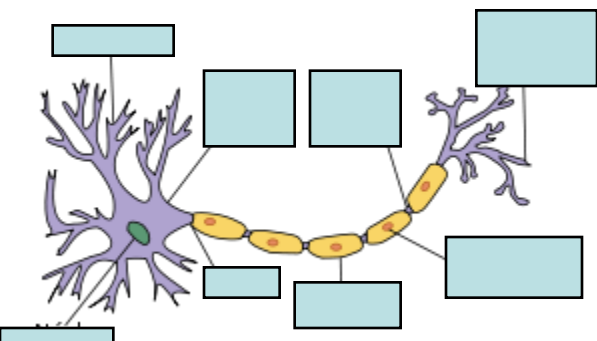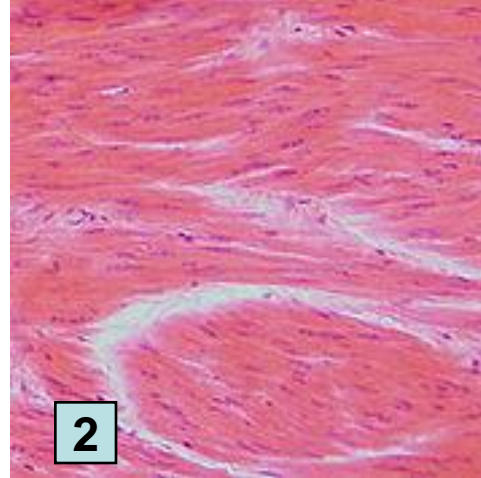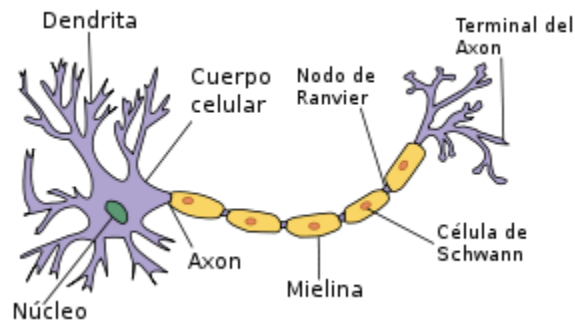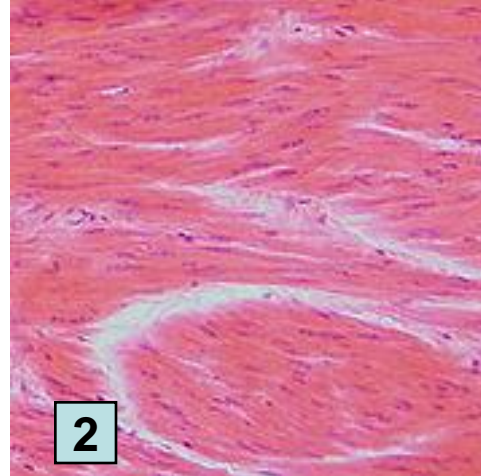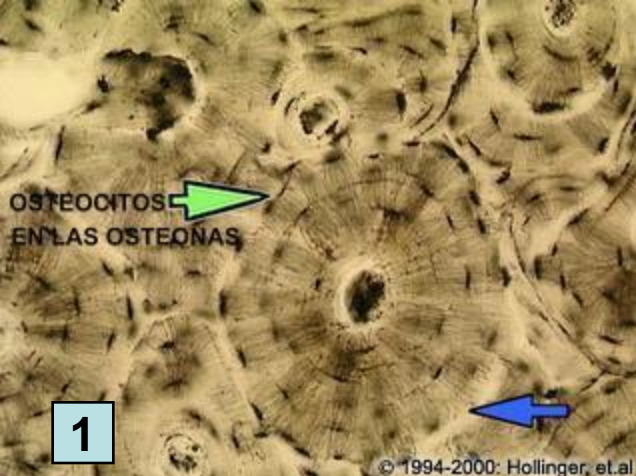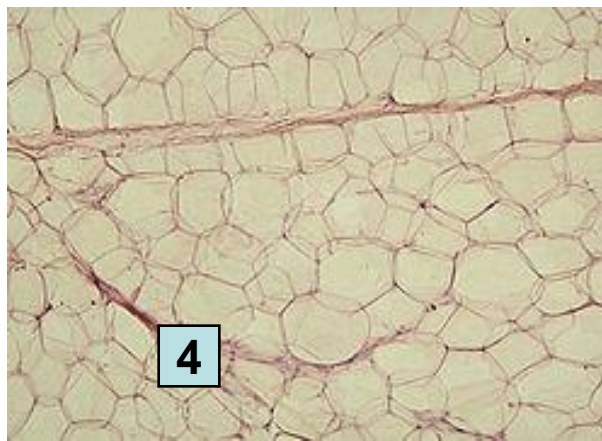
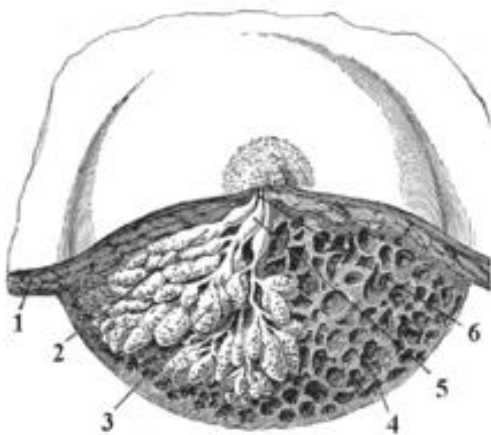
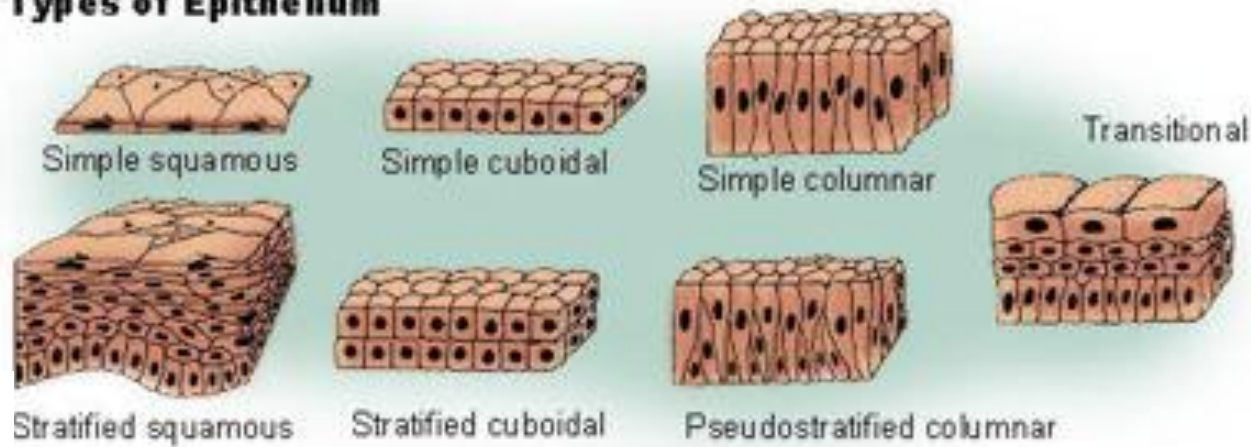
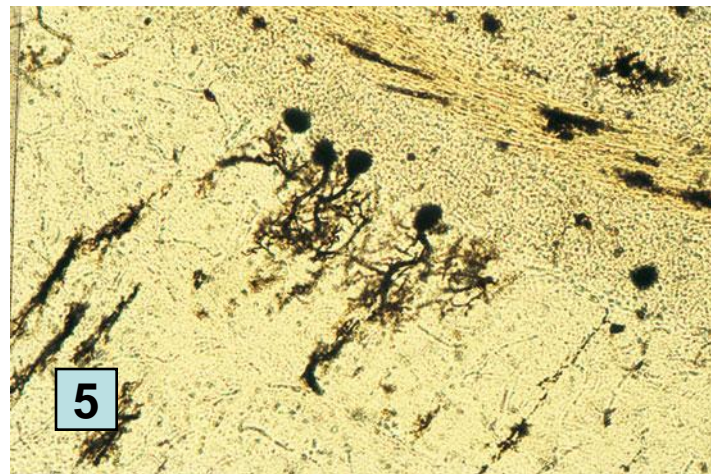
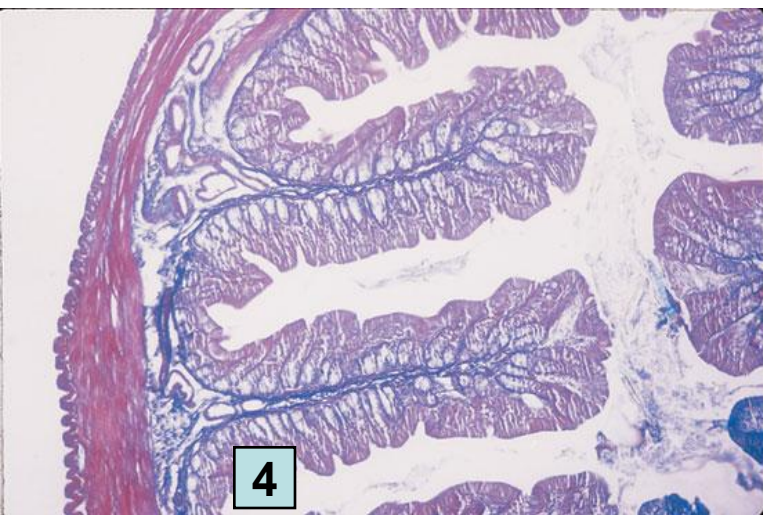
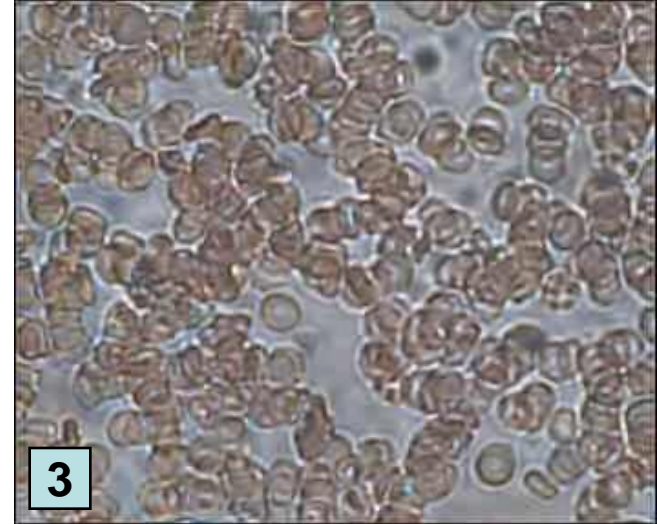
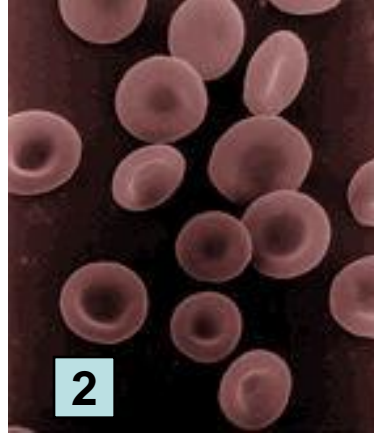
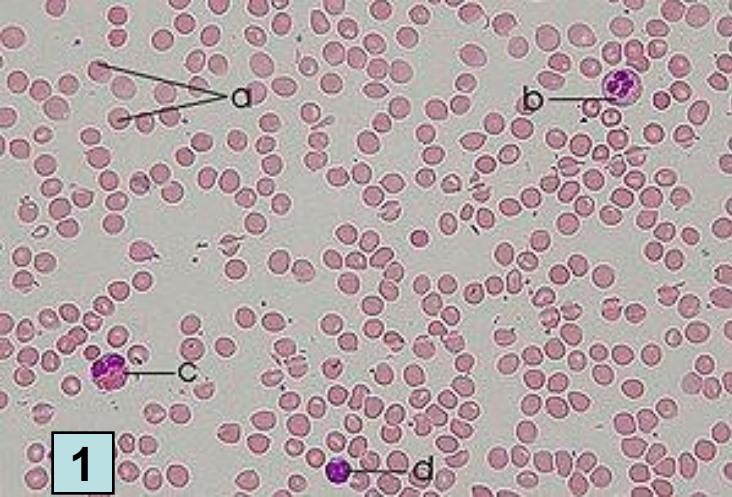
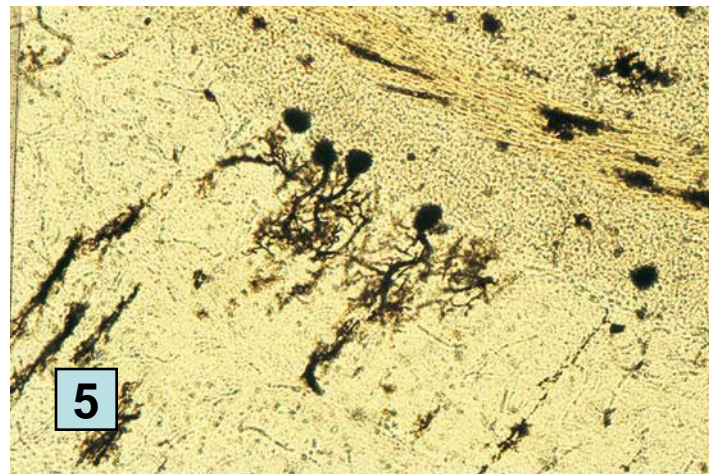
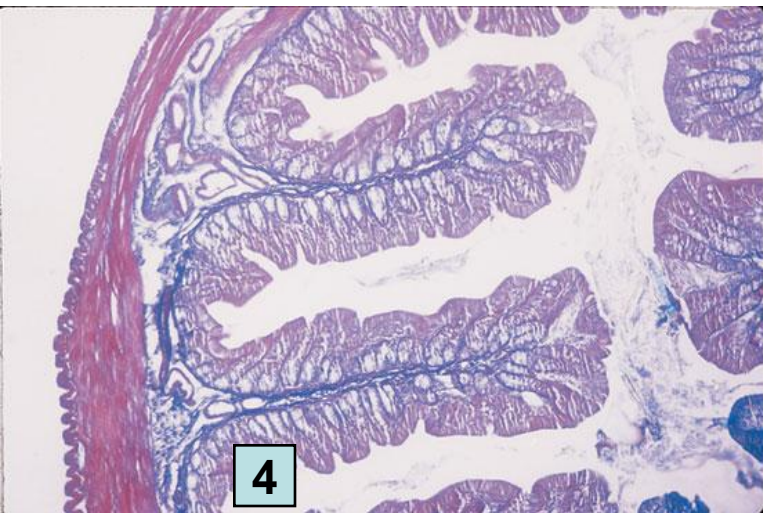
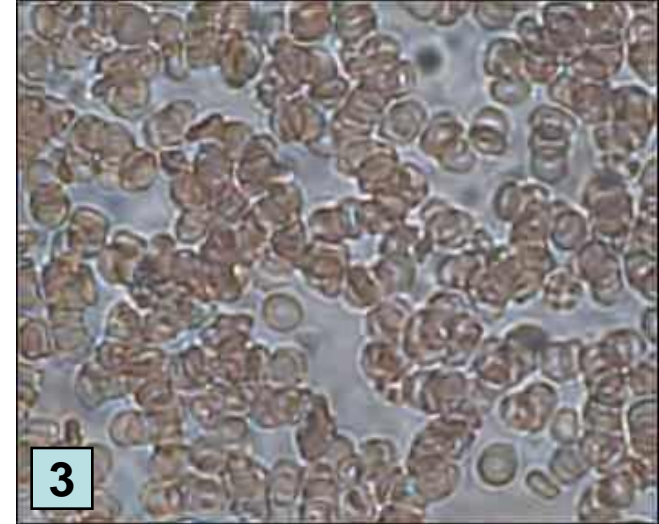
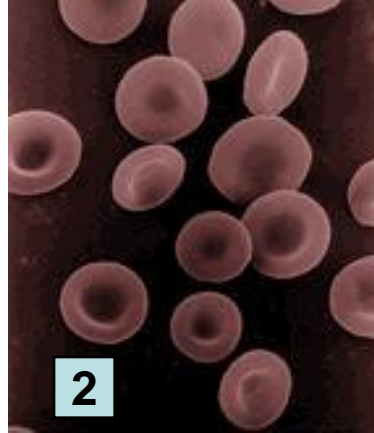
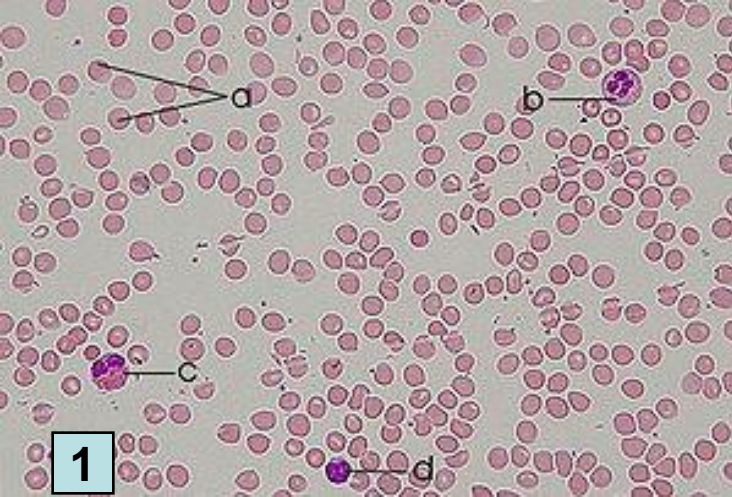


Types of Epithelium



1. Tejido óseo y osteocitos.
2. T. muscular liso
3. T. muscular estriado
4. Tejido adiposo





1. Tejido sanguíneo (a. eritrocitos, b. neutrófilos, c. eosinófilos, d. linfocito)
2. Glóbulos rojos
3. Glóbulos sin tinción
4. Epitelial que tapiza el intestino
5. Nervioso con algunas neuronas

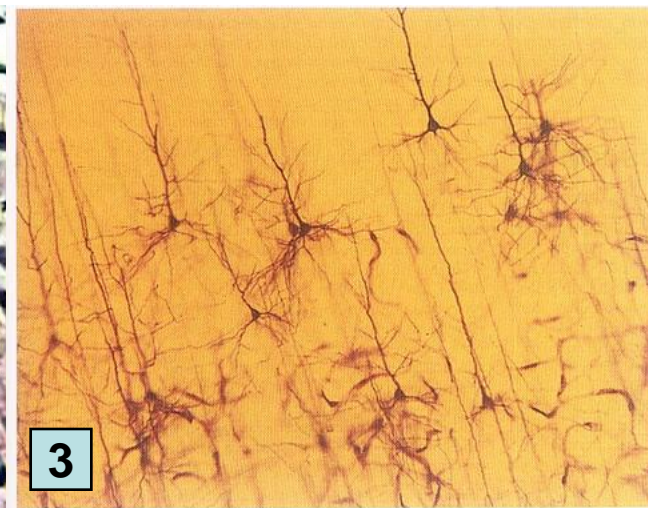
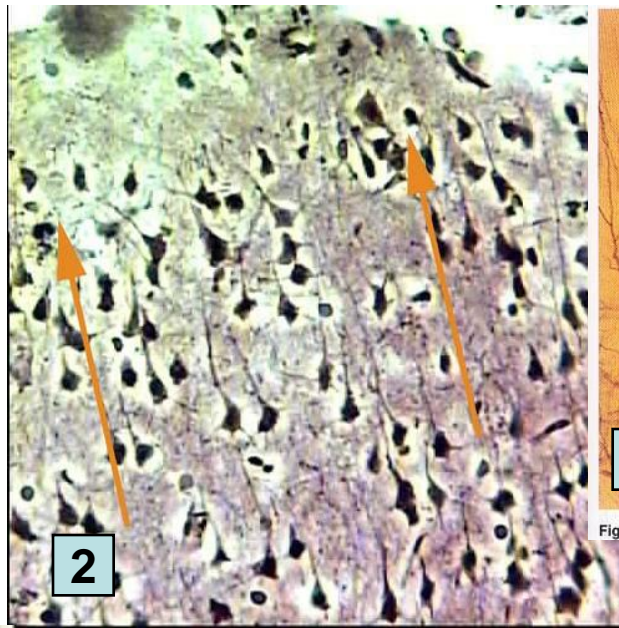
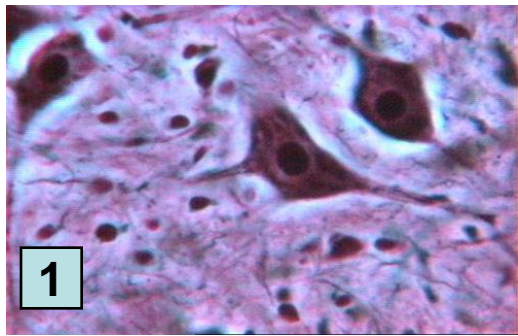
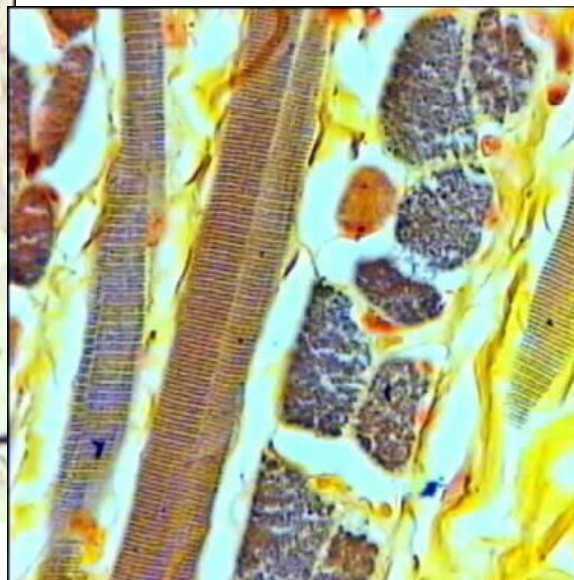
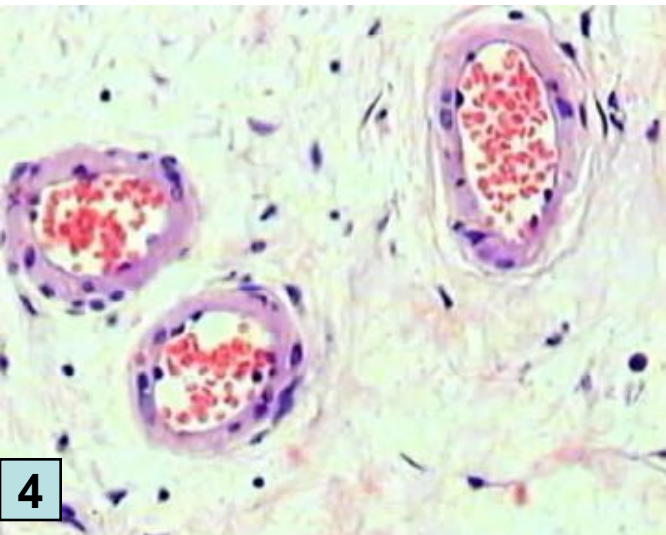


Figura 2-3. Neuronas teñidas con la tinción de Golgi. (De Hubel, 1988, pág. 126.)



5

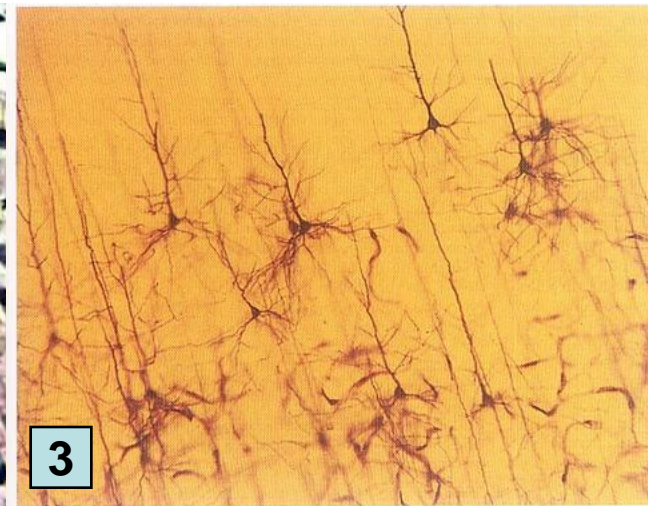
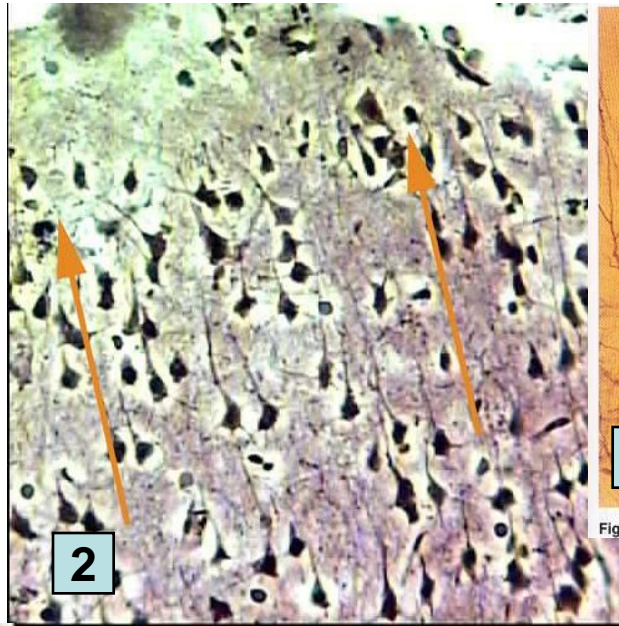
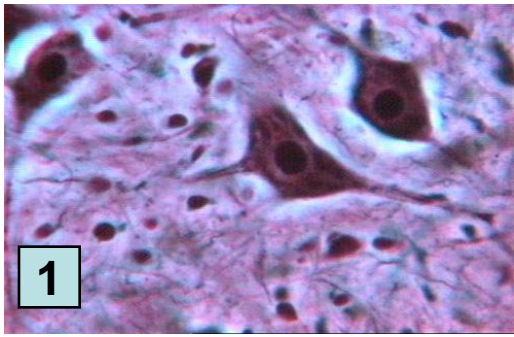
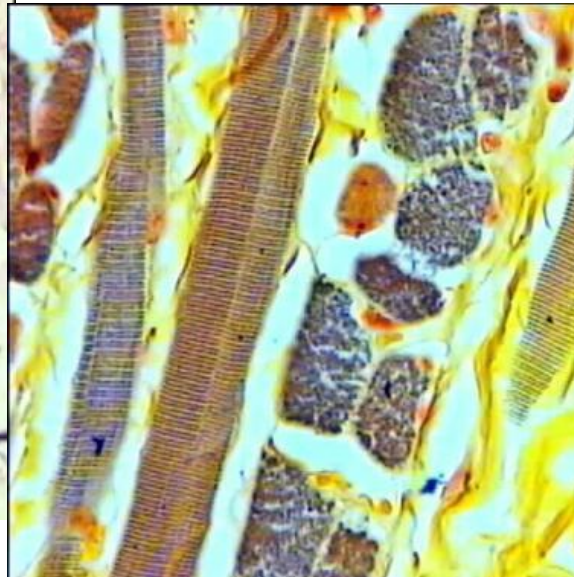
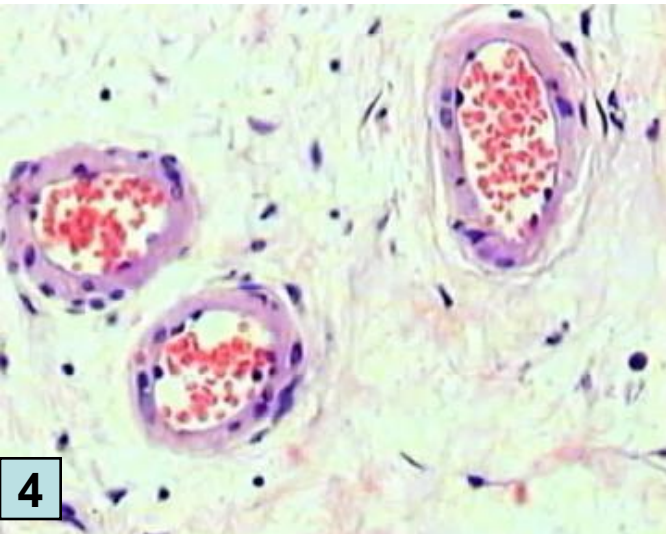
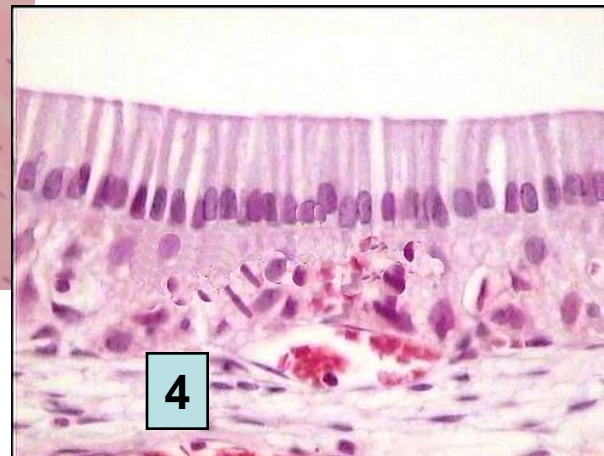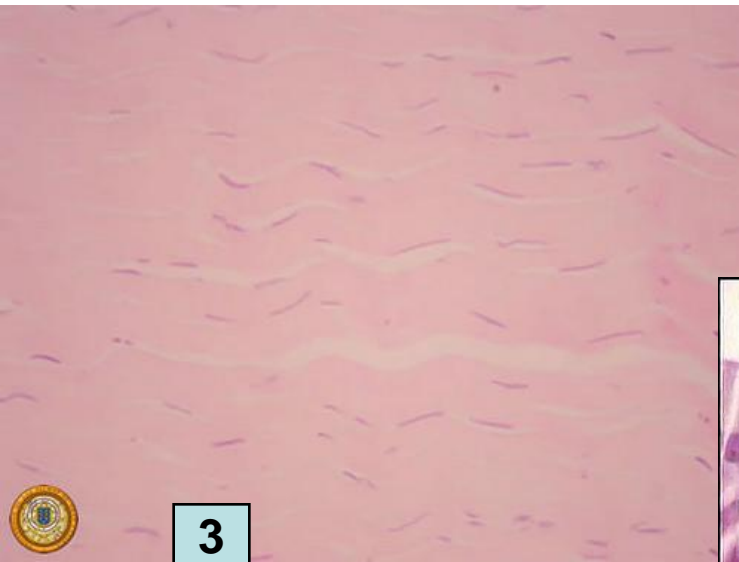
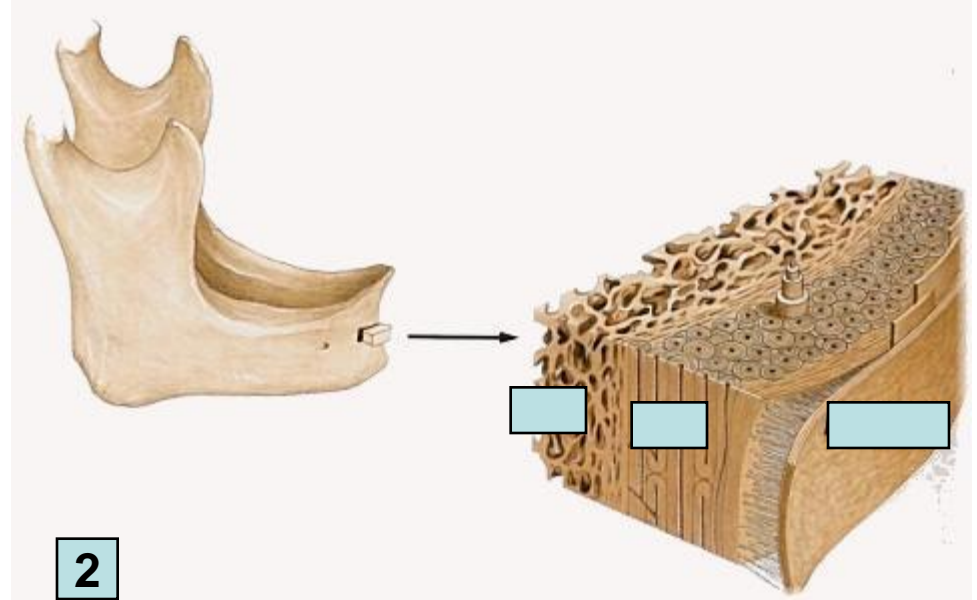
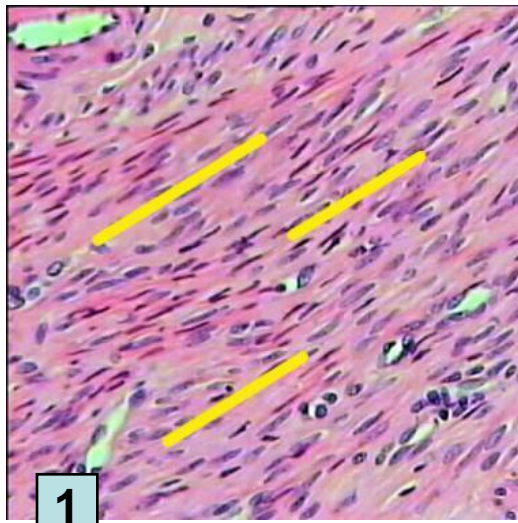
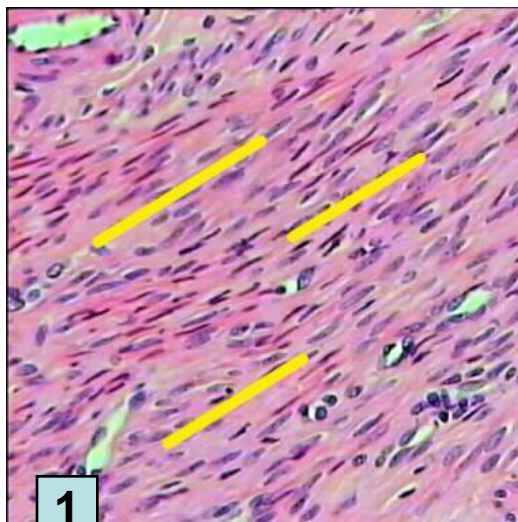


Figura 2-3. Neuronas teñidas con la tinción de Golgi. (De Hubel, 1988, pág. 126.)

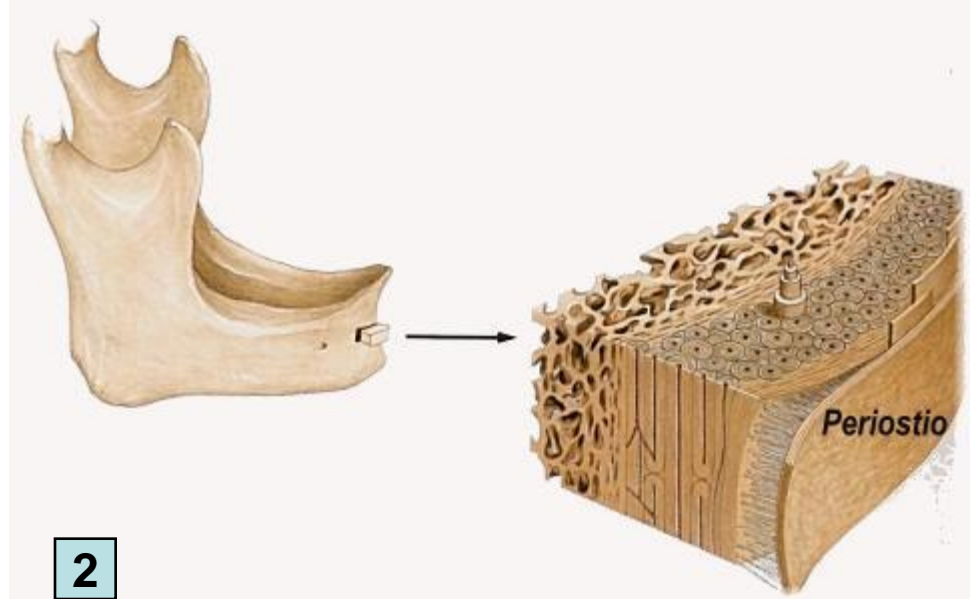


1. T nervioso con neuronas multipolares
2. T. nervioso de la corteza cerebral
3. Tejido nervioso y neuronas teñidas con la tinción de Golgi.
4. Vasos sanguíneos con hematíes y rodeados de conjuntivo
5. Fibras musculares estriadas de la lengua



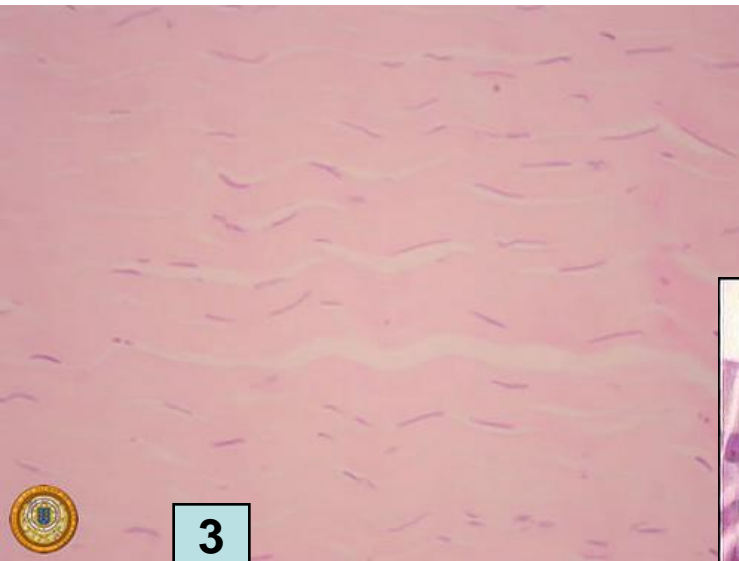


1

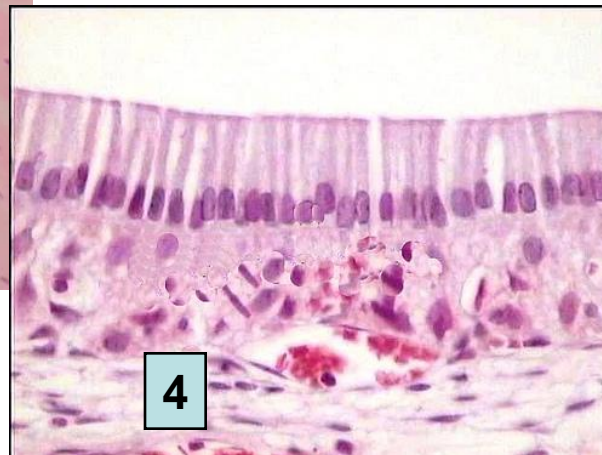

2

Tejido óseo compacto (en el exterior) y esponjoso (en el interior). El periostio es una membrana fibroelástica que cubre la superficie del hueso.

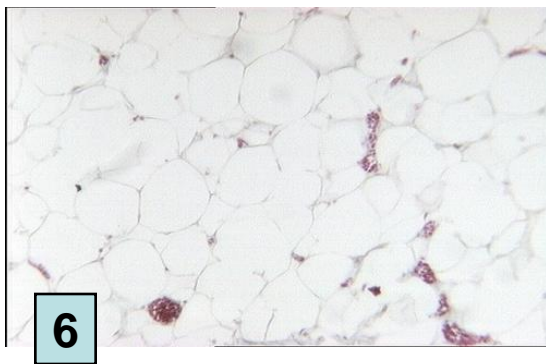
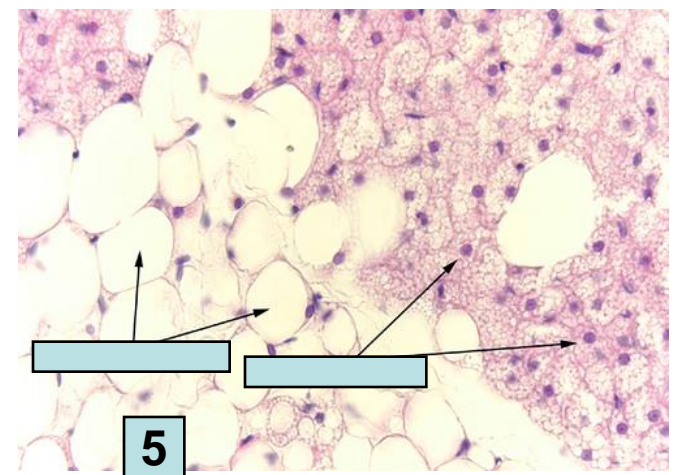
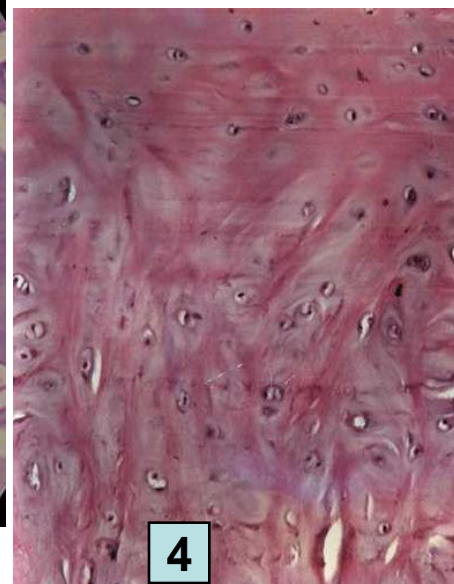
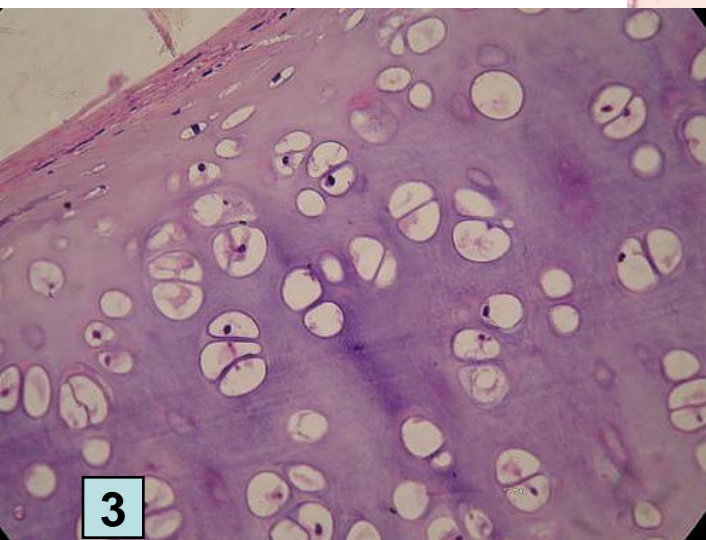
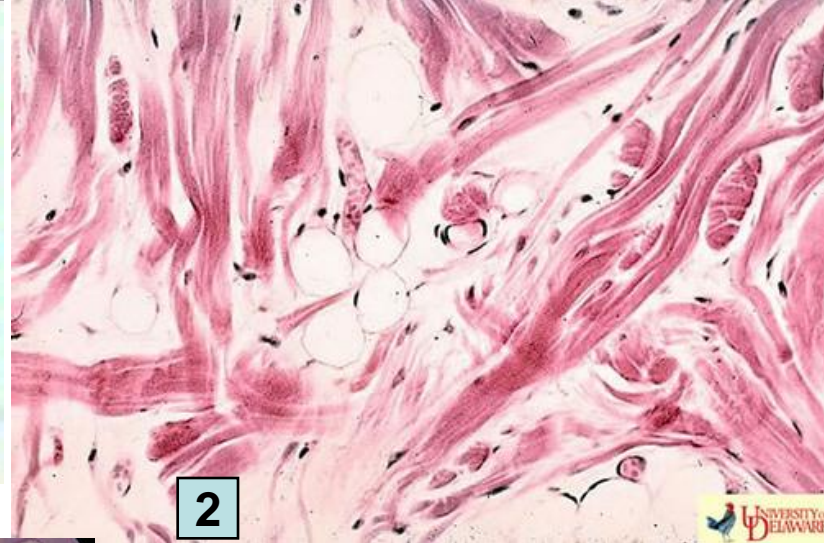
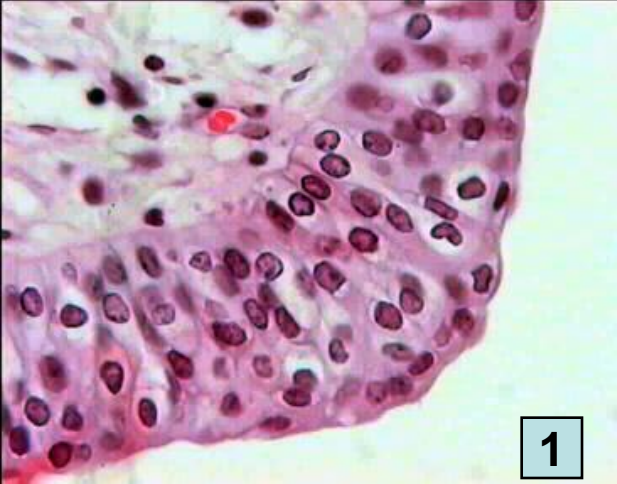
3



4

1. Fibras musculares lisas (secc. Longitudinal)
2. Óseo compacto y esponjoso, periostio y sistemas de Havers
3. Tejido conjuntivo denso
4. T. epitelial cilíndrico

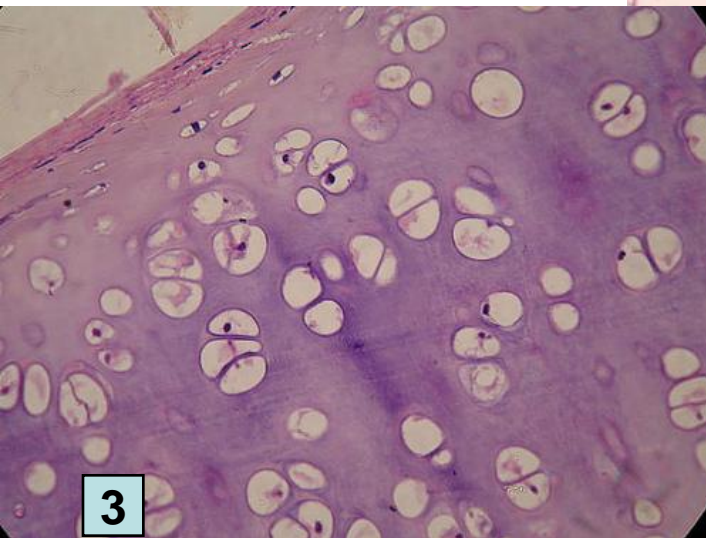




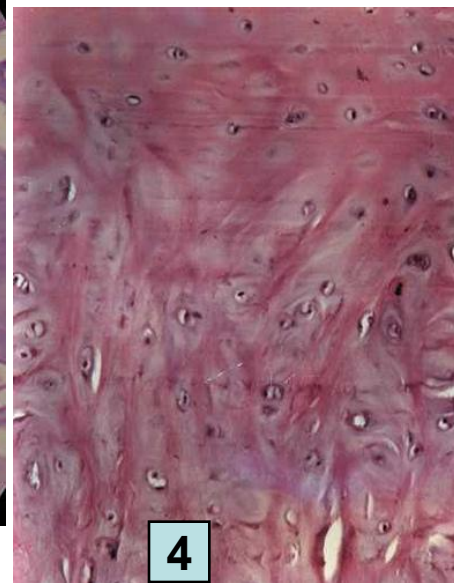
1



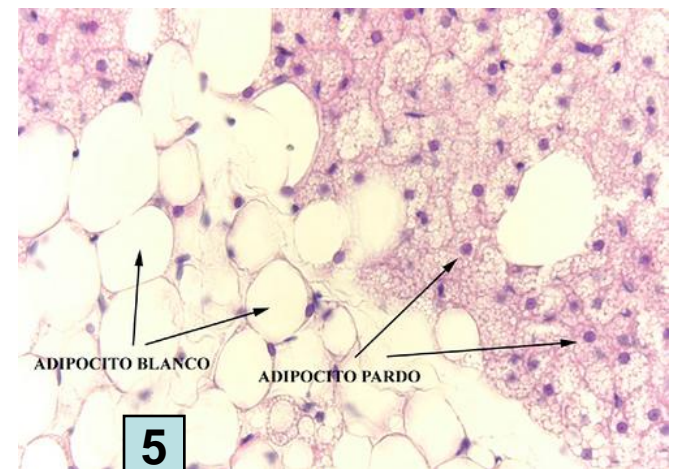
2



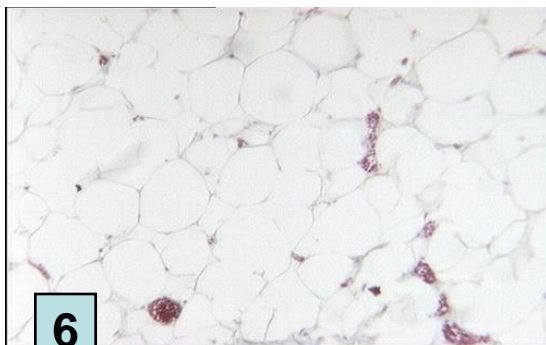
3



4



5



6

1. T. epitelial de transición
2. Conjuntivo denso con fibras de colágeno
3. Cartilaginoso elástico ocupando lagunas entre la matriz
4. Cartílago hialino
5. Adiposo
6. Adiposo sin tinción